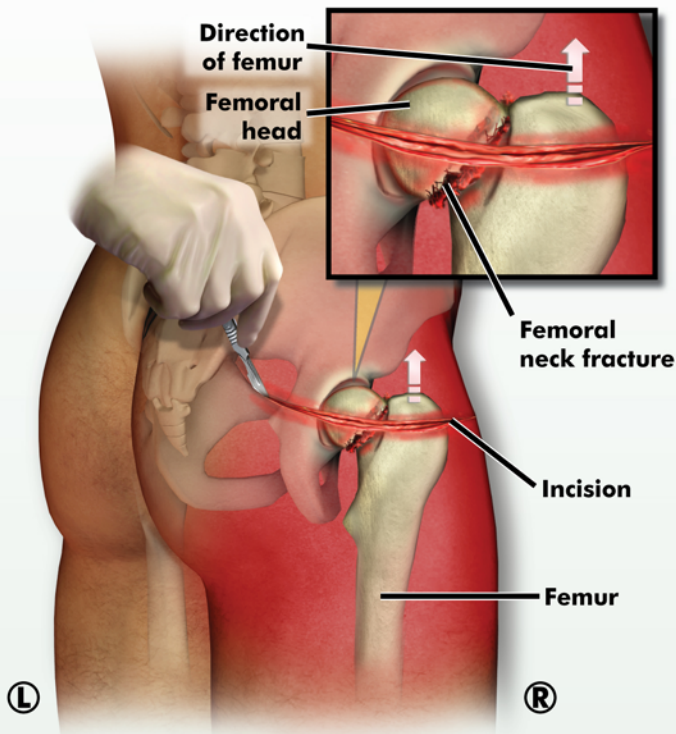


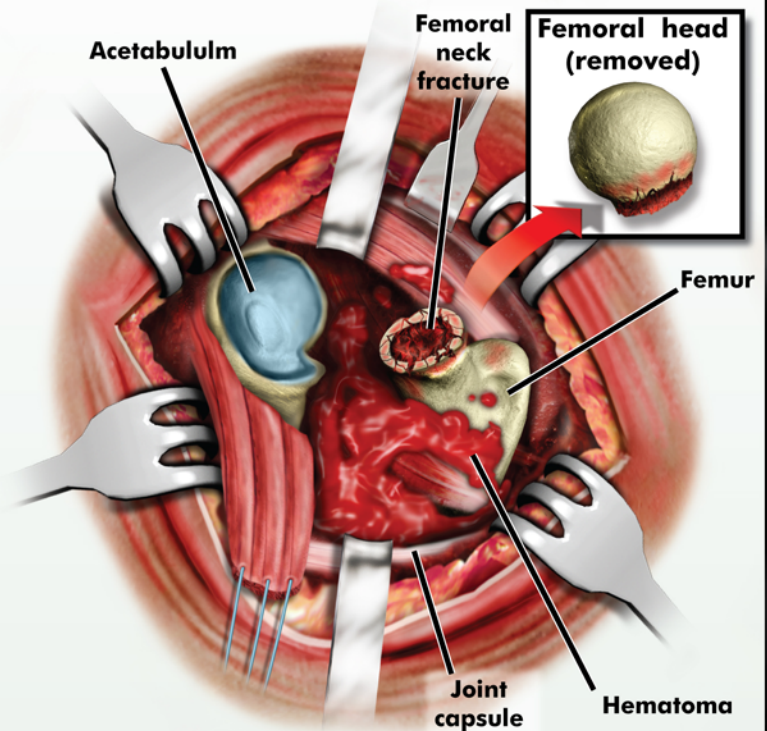
RIGHT HIP BIPOLAR HEMIARTHROPLASTY

POSTEROLATERAL VIEW

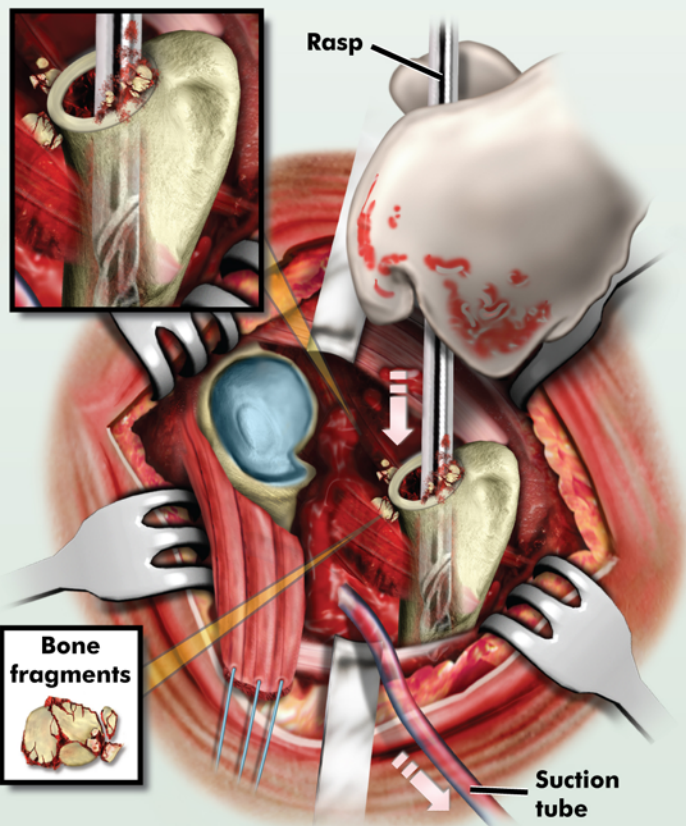


1. The right femoral neck is fractured and the femoral head is displaced. An incision is made at the right hip.

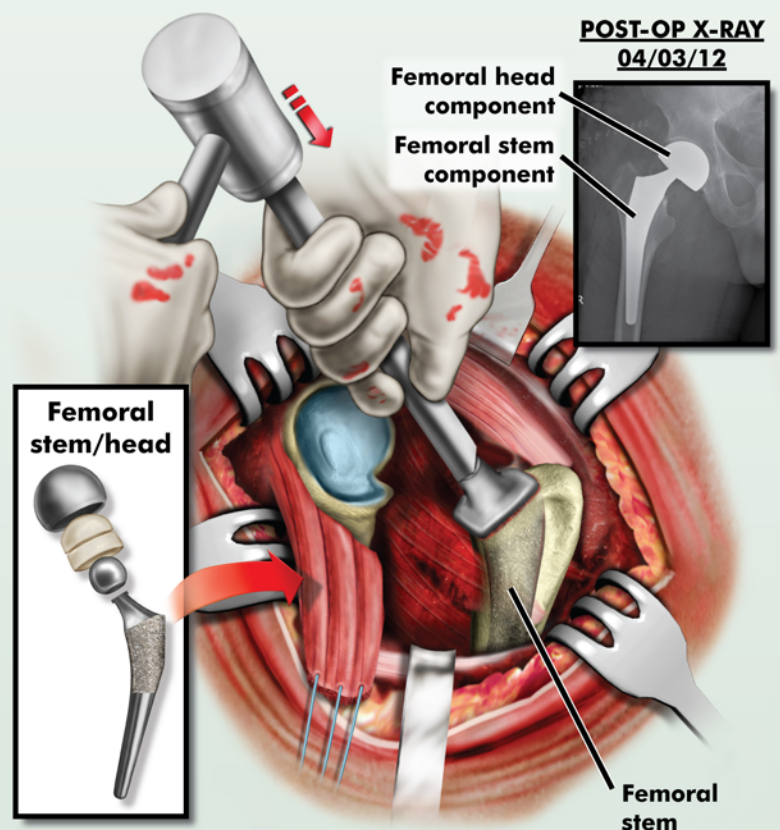
POSTEROLATERAL VIEW



2. The right hip is exposed. The joint capsule is opened and significant hematoma is seen. The femoral head is removed.



3. The posterior aspect of the trochanter is opened up and the femoral canal is rasped. Bone fragments and the hematoma are removed.



4. The femoral stem is impacted in place. The acetabular component/femoral head component is placed. The joint capsule and skin are sutured closed.